

The American Journal of Sports Medicine

<http://ajs.sagepub.com/>

Management of the Helmeted Athlete With Suspected Cervical Spine Injury

Kevin N. Waninger
Am J Sports Med 2004 32: 1331
DOI: 10.1177/0363546504264580

The online version of this article can be found at:
<http://ajs.sagepub.com/content/32/5/1331>

Published by:



<http://www.sagepublications.com>

On behalf of:



<http://www.aossm.org>
American Orthopaedic Society for Sports Medicine

Additional services and information for *The American Journal of Sports Medicine* can be found at:

Email Alerts: <http://ajs.sagepub.com/cgi/alerts>

Subscriptions: <http://ajs.sagepub.com/subscriptions>

Reprints: <http://www.sagepub.com/journalsReprints.nav>

Permissions: <http://www.sagepub.com/journalsPermissions.nav>

Management of the Helmeted Athlete With Suspected Cervical Spine Injury

Kevin N. Waninger,* MD

From the Department of Emergency Medicine, Saint Luke's Hospital, Bethlehem, Pennsylvania

Improper handling of an unstable neck injury may result in iatrogenic neurologic injury. A review of published evidence on cervical management in the helmeted athlete with a suspected spinal injury is discussed. The approach to the neck-injured helmeted athlete and the algorithms for on-field and emergency department evaluations are reviewed. The characteristics of the fitted football helmet allow safe access for airway management, and helmets and shoulder pads should not be initially removed unless absolutely necessary. Prehospital and emergency personnel should be trained in the indications for removal and in proper helmet, shoulder pad, and facemask removal techniques. If required, both helmet and shoulder pads should be removed simultaneously. Radiographs with equipment in place may be inadequate, and the value of computed tomography and magnetic resonance imaging in these helmeted patients has been studied. If adequate films cannot be obtained with equipment in place, helmet and shoulder pads may need to be removed before radiographic clearance. A plan should be formulated to prepare for such unexpected clinical scenarios as cervical spine injuries, and skills should be practiced. Airway and cervical spine management in these helmeted athletes is an area of ongoing research.

Keywords: helmet removal; cervical spine; football; ice hockey; trauma; sports; injury

Contact sports present a small but inherent risk of cervical spine injury. There is the potential for spinal instability following cervical trauma, and full assessment of the cervical spine is difficult in the prehospital setting.³⁷ The injured athlete with a protective helmet in place presents a unique clinical scenario.¹⁸² The injured athlete must be handled cautiously until the extent of skeletal and neurologic injury can be defined, and improper handling of an unstable cervical spine may result in iatrogenic neurologic injury.³² Proper handling techniques are required to minimize neurologic sequelae, expedite treatment, and prepare the injured athlete for transportation to the hospital.^{6,22} Both prehospital and emergency department personnel must be aware of the injury patterns and equipment involved in these injuries to safely care for the injured helmeted athlete.

The protective helmet and shoulder pads worn by athletes introduce special considerations during the initial evaluation, stabilization, immobilization, and transport of injured athletes. There are still management issues that exist with these patients.^{72,182} Most helmet research has been directed at motorcycles,^{10,19,50,112,175} American football,[†] and ice hockey.[‡] The data are limited evaluating equipment worn in lacrosse,^{24,25,155,184} rugby,^{13,43,130,149,188,190}

equestrian sports,^{17,70,119,187} baseball/softball, kayaking, skiing/snowboarding,^{77,167} bicycling,^{26,57} skateboard/roller skating/in-line skating,¹²¹ and even cricket,¹⁰⁸ bull riding,¹⁸ and touch football.⁹⁸ Helmet management in sports like football, hockey, and lacrosse is complicated by the additional presence of shoulder pads. Results from studies evaluating one helmet may not be applicable to other helmet designs. The role played by the mouthpiece has been studied in concussions^{159,191} but has not been considered in cervical spine injuries.

This article will review on-field and emergency department management of the helmeted athlete with a potential cervical spine injury. A review of the literature for facemask and helmet/shoulder pad management and removal is discussed.

METHODS

Computerized bibliographical databases (Medline, Sportdiscus) without language restrictions were searched to identify all relevant studies. The search covered the time period of January 1966 to December 2003 using the following keywords: *cervical spine, football, helmet, injury, and sports*. To be included, a study had to meet the following criteria:

1. The study must be a report published in a peer-reviewed journal by December 2003.

*Address correspondence to Kevin N. Waninger, MD, 211 North Barrington Court, Newark, DE 19702 (e-mail: knwaninger@aol.com).

No author or related institution has received any financial benefit from research in this study.

[†]References 38, 112, 123, 132, 141, 166, 169, 176, 184.

[‡]References 12, 99, 111, 132, 145, 160, 184.

2. The study design must be either case control, cross sectional, or cohort. Case reports and surveys that were relevant to the subject were included. Review articles were included in the text but were not included in the tables.
3. Abstracts were included only if the research was reported as an abstract in a peer-reviewed format but was not subsequently published. Research published only as an abstract is clearly identified in the References section.

Abstracts of all relevant studies identified were read. If the abstract met the criteria outlined above, the full article was retrieved and reviewed. If no abstract was available, or if, based on the abstract, it was unclear whether a study should enter this systematic review, the article was reviewed. Studies not meeting the predetermined criteria were not reviewed. Research lists of included articles were searched for additional references. Reviews of the athletic training, emergency medicine, internal medicine, orthopaedic, radiology, and sports medicine literature identified additional articles.

MECHANISM OF INJURY

In contact sports such as football, the cervical spine is repeatedly exposed to potentially injurious cervical spine forces. Fortunately, most forces are dissipated by the cervical paravertebral muscles and the intervertebral discs through controlled spinal motion. However, the vertebrae, intervertebral disks, and supporting ligaments can be injured when contact occurs on the crown of the helmet and the body is positioned such that the force vectors are transmitted along the vertical axis of the cervical spine.^{14,44,170,172}

Flexion and axial loading have been implicated in the majority of cases, although extension, lateral stretch, and congenital instability have also been reported.⁴⁹ When the neck is in the neutral position, the cervical spine is slightly extended because of the normal lordotic curve. With the lordotic curvature of the cervical spine, energy is dissipated tangentially when the cervical spine is axially loaded. When a player flexes the neck 30° to tackle,^{64,65} block, or ram an opponent, the cervical spine is straightened, converting the protective lordotic cervical spine into a segmented column (Figures 1, 2A, and 2B). When the spine is in this straightened position and force is directed along its longitudinal axis, the intervertebral disks at first absorb the energy and are compressed. When maximum deformation is reached, continued compressive forces cannot be dissipated by controlled motion in the spinal segments, resulting in angular deformation and buckling with failure of the intervertebral discs and/or bony elements (Figure 2C). The resulting injury is a subluxation, facet dislocation, or fracture dislocation at 1 spinal level.^{44,172} Direct contact from the posterior rim of the helmet has been discounted as a significant mechanism of injury.¹⁷⁹ The development of strong neck musculature




Figure 1. A college defensive back (dark jersey) is shown ramming an opposing ball carrier with his head, resulting in severe axial loading of his cervical spine. This defensive player suffered fractures of C4, C5, and C6 vertebrae and was rendered quadriplegic. (Reprinted with permission from Torg JS, *Athletic Injuries to the Head, Neck, and Face*, Philadelphia, Pa: Mosby Year Book; 1991, p 492.)

could reasonably be expected to prevent some neck injuries, and isometric and resistance exercises should be a part of preseason conditioning for contact athletes.¹²⁵ A similar mechanism of axial loading of the spine is implicated in ice hockey, when hockey players are hit from behind and driven into the wall with a hyperflexed neck, an infraction referred to as “boarding.” Data collected since 1977 outline the patterns of cervical spine injuries that have occurred in football¹¹⁶ (Appendixes 1-5, available in the online version of this article at www.ajsm.org).

Rule changes and educational efforts directed at athletes, coaches, and parents have been successful in decreasing the amount of cervical injuries. A high percentage of players, when surveyed, displayed poor knowledge of the dangers of “spearing” in football.¹⁰⁰ Rules that penalize for spearing (hitting another player with the top of the head), instituted in 1976 by the National Collegiate Athletic Association (NCAA) and the National Federation of High Schools, coincide with the dramatic decrease in the number of cervical spine injuries in football^{104,116,172} (Figure 3). In an attempt to decrease the escalating number of cervical spine injuries in amateur hockey players, a coordinated educational program referred to as Safety Toward Other Players (STOP) provides a visual reminder for all players not to hit an opponent from behind, with STOP patches sewn above the numbers on the back of the jerseys (Figure 4). An accompanying educational program helps coaches teach players about the dangers of checking from behind. Some authors recommend that all body checking be banned at the amateur level to prevent injury.^{27,146}

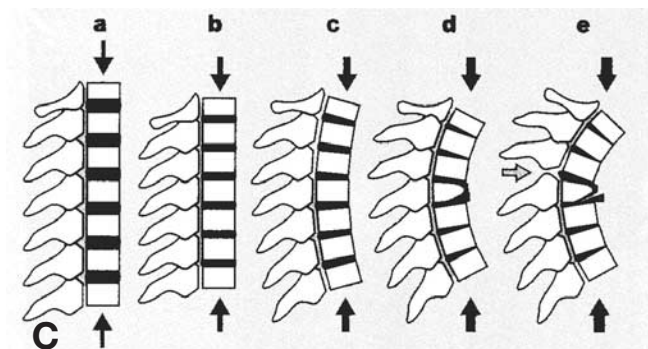
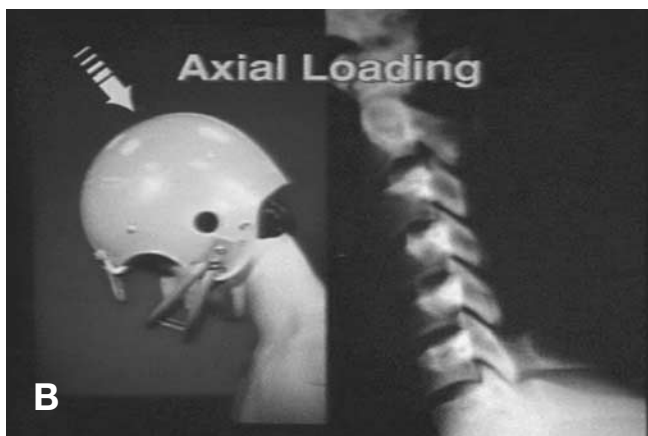
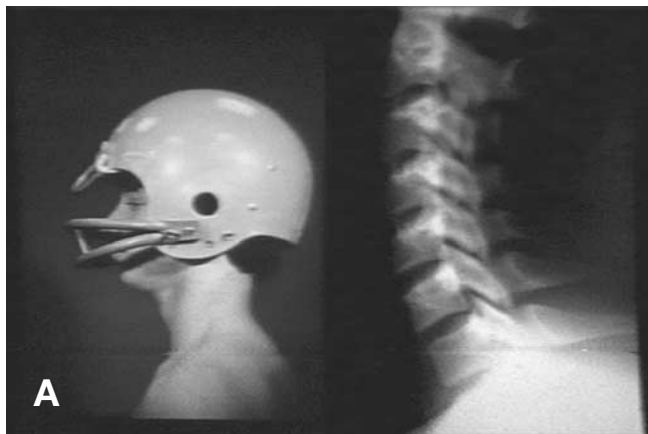


Figure 2. A, when the head and neck are in a normal upright position, the cervical spine is slightly extended because of a natural cervical lordosis; B, when the neck is flexed 30°, the cervical spine is straightened, converting it into a segmented column. (A and B reprinted with permission from Torg et al.¹⁷³) C, the straightened cervical spine behaves like a segmented column when it is subjected to an axial loading force. The force first causes compressive deformation of the intervertebral disks (a, b). As the energy input continues and maximum compressive deformation is reached, the spine flexes and buckles (c) with resulting fracture, subluxation, or dislocation (d and e). This sequence of events occurs in as little as 8.4 ms. (Reprinted with permission from Torg et al.¹⁷²)

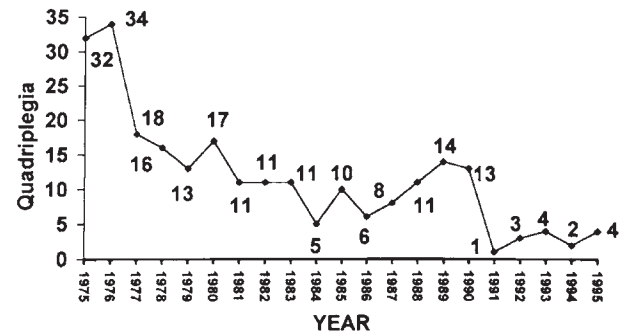


Figure 3. The yearly incidence of permanent cervical quadriplegia for all levels of participation (1975 to 1995) decreased dramatically in 1977 after initiation of the rule changes prohibiting the use of head first tackling and blocking techniques. (Reproduced with permission, Torg et al.¹⁷²)

MANAGEMENT OF THE HELMETED ATHLETE

The management of the neck-injured helmeted athlete begins on the field with proper positioning and immobilization of the cervical spine. Immobilization of the neck in a neutral position restricts movement of the unstable vertebral column in an effort to prevent damage to the enclosed spinal cord and nerve roots. Flexion and extension posturing of the traumatized neck may result in cord deformation and elongation of the neutral axis. Small amounts of abnormal intervertebral motion may cause damage.³³ This is especially true in the subaxial spine, because the cord in this area demonstrates an exceptional intolerance of even small amounts of segmental elongation or deformation.¹⁰¹

Radiographic studies are required to accurately identify the presence or absence of a fracture or injury that would render the cervical spine unstable.^{36,37,46,118,189} Although guidelines for clearance of the cervical spine without radiographic studies have been published,^{69,161} most injured athletes would not qualify for clearance under these guidelines because of the mechanism of injury. Because a potential cervical spine injury cannot be fully ruled out on the field, the goal for emergency management is the safe, expeditious transport of the injured player to a medical facility with radiographic capabilities. A systematic, organized protocol for this management is essential to prevent further injury.⁷ This involves communication between all parties involved in the care of the patient. In the past, there has been considerable debate over protocols for removal of equipment during on-field or transport management of helmeted football players with suspected neck injury. Inconsistencies in the treatment of football neck injuries in the prehospital setting have been well documented.^{72,182} The rationale for leaving the protective equipment in place is to prevent progressive neurologic injury via inadvertent movement of an unstable cervical spinal segment. Experimental evidence demonstrates both the detrimental effect of continued compression⁵⁴ and the protective effect of immediate immobilization on the injured spinal cord.³⁹ The need for immobilization begins at the site of the injury,



Figure 4. Safety Toward Other Players (STOP) patch worn on the back of an amateur hockey player as a visual reminder for players not to hit an opponent from behind.

continues during transport and emergency department stabilization, and ends only when a cervical spine injury has been ruled out or definitively stabilized.¹³¹

There is a consensus on the removal of protective gear during the initial on-field assessment of the injured athlete. Sports medicine professionals universally discourage removal of a football helmet and shoulder pads when any cervical spine injury is suspected.^{153,182} Several studies have documented that the excessive movement resulting from helmet and shoulder pad removal may put the patient at risk (Table 1).⁸ The NCAA guidelines for football helmet management state that unless there are special circumstances, such as respiratory distress coupled with an inability to access the airway, the helmet should not be removed on the field when there is a potential head or neck injury.¹¹⁷

Airway Management

When serious injury occurs involving the head and/or spine, at times complicated by altered levels of consciousness, protective equipment such as helmets and shoulder

pads may provide a hindrance to safe airway management. Airway obstruction from the tongue, mouth guard, or a foreign body is a possibility, with restoration of breathing as simple as establishing a patent airway. Chin lift–jaw thrust maneuvers should be initially accomplished without removing the football helmet or the facemask. In most unconscious athletes, these maneuvers will result in restoration of a patent airway. If these maneuvers do not succeed in restoring airway and breathing, alternative methods to gain rapid access to the airway and restore breathing must be implemented, such as a CPR pocket mask,^{83,139–141} bag valve mask/advanced airway maneuvers (Table 2), helmet removal (Table 3), and/or facemask removal (Table 4).

Despite the fact that neurologic causes of cardiac arrest can occur with cervical spine injury above the C4 level,^{41,151} respiratory arrest secondary to spinal cord injury or cardiac arrest in the helmeted athlete is rare. The majority of football-related cervical spine injuries occur anatomically in the C5 to C7 vertebrae, and respiratory compromise with the need for airway control does not usually occur at these levels.^{41,182} However, the potential for respiratory compromise requiring ventilatory support exists because cervical spine fractures and instability above C4 have been reported.¹¹ Despite the small number of reported cases of cervical spine-injured football players requiring intubation, the recent case of a professional football player requiring on-field intubation has brought this clinical issue to the forefront.² Although cases of simultaneous cervical spine injury and intracranial injury have been noted in unhelmeted pediatric sports trauma,²⁸ no cases of helmeted athletes with simultaneous cervical spine and intracranial injury have been reported.

In athletes with cervical spine injury and respiratory or cardiac involvement requiring airway management, protocols for equipment removal and cardiopulmonary resuscitation have been established,^{41,153} although the safety and efficiency of these protocols have not been well studied. When the decision is made that the helmeted athlete requires airway control, standard techniques with in-line stabilization are recommended.¹³⁶ The airway maneuvers and techniques that cause the least cervical spine movement have been debated and are not well studied in the helmeted athlete (Table 2). Practitioners should choose the airway method and technique with which they have the greatest experience and skill. Neurologic deterioration from spinal cord injury may be associated with airway management.^{63,115}

There has been concern from prehospital personnel regarding the inability to fully evaluate the helmeted head and neck before transport for secondary injuries. However, the velocity of football contact is much less compared to vehicular trauma, and football does not usually cause the degree of underlying head injuries—requiring aggressive secondary survey evaluation—that may be seen with motorcycle injuries.^{42,182} Many of the cervical spine management protocols were designed for motorcycle helmets.^{19,21,50,58,109} Motorcycle helmets are often designed

⁸References 10, 38, 51, 73, 99, 111, 112, 123, 132, 160, 166, 169.

¹¹References 2, 49, 110, 151, 171, 174, 182.

TABLE 1
Helmet and Shoulder Pad Removal Studies

References	Subjects	Methods	Subjects	Number of Techniques	Limitations	Results	Recommendations
Aprahamian et al ¹⁰	Cadaver (with and without surgically created C5-C6 instability)	Clinical palpation	N = 1	Helmet removal monitored by palpation only	Cadaveric study; motorcycle helmets; defects monitored by palpation; case study	Helmet removal techniques adversely affected preexisting injury	Do not remove helmet unless necessary; consider removal of motorcycle helmets with cast cutters
Donaldson et al ³⁸	Cadaver (with and without surgically created C1-C2 and C5-C6 instability)	Video fluoroscopy	N = 6	Helmet and shoulder pad removal	Cadaveric study; football only	Unacceptable amount of movement with helmet and pad removal	Helmet and shoulder pad removal should be performed in a carefully monitored setting by at least 3 or 4 trained people
Gastel et al ⁵¹	Cadaver (with and without surgically created C5-C6 instability)	Radiographs	N = 8	Helmet removal: no equipment; shoulder pads only; helmet and pads in place	Cadaveric study; football only	To maintain neutral position, helmet and shoulder pads should be removed together	Helmet removal should be delayed until both helmet and shoulder pads can be removed together in a controlled setting
Iselborn et al ⁷³	Human volunteers	Radiographs	Not recorded	Degrees of movement at C5 spinal segment during helmet removal	Abstract only; spinal movement that is clinically relevant unknown; technique to measure movement with radiographs	Unacceptable amount of movement with helmet removal attempts	Helmet removal techniques, flexion and lateral rotation of helmeted head produce unacceptable amounts of movement at C-5
Metz et al ¹¹¹	Human male volunteers	Radiographs	N = 8	Lateral radiographs without equipment; shoulder pads only; helmet and pads in place	Healthy volunteers; hockey only	Significant movement of cervical spine with pads and no helmet	Immobilization with both helmet and pads, removal together after initial radiographs; secure chin to prevent head/neck motion
Meyer and Daniel ¹¹²	Human male volunteers	Fluoroscopy and radiographs	n = 17 (static); n = 9 (fluoroscopy)	Comparison of 1-person and 2-person helmet removal techniques	Healthy volunteers; motorcycle helmets	No difference in cervical motion with either removal technique	Helmet may be used to apply traction; helmet removal not required in the field unless airway problems exist
LaPrade et al ⁹⁹	Human male volunteers	Lateral scout CT scans	N = 10	Comparison of lateral radiographs with no equipment; pads only; helmet and pads	Healthy volunteers; hockey only	With helmet removed and shoulder pads in place, increased cervical lordosis (extension)	Removal of hockey helmet not recommended; it may lead to unnecessary cervical spine motion
Palumbo et al ¹²³	Cadaver (with and without surgically created C5-C6 instability)	Radiographs	n = 15 (intact); n = 8 (C5-C6 instability)	Helmet removal: no equipment; helmet only; pads only; helmet and pads	Cadaveric study; football only	Increased movement with "helmet only" and "pads only"	Helmet-only and pads-only immobilization violates the principle of splinting the cervical spine in neutral; removal of pads is an "all or none" proposition

(continued)

TABLE 1
Continued

References	Subjects	Methods	Subjects	Number of Techniques	Limitations	Results	Recommendations
Peris et al ¹²⁹	Human male volunteers	Fluoroscopy and radiographs	N = 7	Helmet and shoulder pads are removed according to NATA ^a protocol; disk height, translation, angulation, cord space compared to baseline	Uninjured healthy volunteers	Only minimal changes from baseline for each study parameter during the removal protocol	The NATA protocol for helmet and shoulder pads removal effectively limits motion of the cervical spine
Prinsen et al ¹³²	Human male volunteers	Fluoroscopy and radiographs	n = 11 (football); n = 10 (hockey)	Cervical displacement during helmet removal, during cervical collar application, and without helmet; pads remained in place	Healthy volunteers; football and hockey helmet data combined	Documented alterations in cervical vertebrae positioning during helmet removal, cervical collar application, head at rest	Helmet removal by prehospital personnel not recommended unless specific clinical indication and personnel are trained in helmet removal
Stephenson et al ¹⁶⁰	Human male volunteers	Radiographs	N = 13	Helmet removal: no equipment; helmet only; pads only; helmet and pads	Abstract only; healthy volunteers; hockey only	Ice hockey helmet removal alters cervical alignment when pads left in place	Helmet removal should be delayed in hockey until both helmet and shoulder pads can be removed together in a controlled setting
Swenson et al ¹⁶⁶	Human male volunteers	Lateral scout CT scans	N = 10	Helmet removal: no equipment; shoulder pads only; helmet and pads	Healthy volunteers; football only	Increased cervical lordosis with pads only; no difference with no equipment and both helmet and pads in place	Helmet removal should be delayed until both helmet and shoulder pads can be removed both helmet and together in a controlled setting
Tierney et al ¹⁶⁹	Human male volunteers	MRI	N = 12	No equipment; helmet and pads; measure sagittal space of cord (SS), cord diameter (SD)	Clinically significant amount of SS and SD unclear; football only	SS greater supine and with pads	Helmet and pads should be maintained during spine board immobilization
Waninger et al ¹⁸⁴	Human male volunteers	High-resolution cameras; video motion analysis	N = 30	Helical angles determine range of motion inside immobilized helmets and pads	Football, ice hockey and lacrosse; amount of clinically significant movement unclear; extrapolated head-to-neck motion	Range of motion inside all 3 helmets was not significantly different	Supports the safety of prehospital stabilization with helmet/pads in place in all 3 sports

^aNATA, National Athletic Trainers' Association.

with a continuous solid "full-face" guard that limits access to the face and airway (Figure 5D).¹⁹ Some studies have reported that removal of motorcycle helmets may not be without the risk of iatrogenic morbidity.^{10,112} However, unlike football injuries, the high-velocity vehicular trauma encountered in motorcycle accidents often involves greater head and neck trauma, including cervical spine injuries above the level of C4. A comprehensive secondary survey of the face and head may require removal of the bulky motorcycle helmet before transport, despite the risk. Supervised

self-removal by the conscious patient may be an option for motorcycle helmet removal.¹⁹ The supervised self-removal of the protective helmet in athletes has not been investigated.

Radiographs

The NCAA¹¹⁷ and the Inter-Association Task Force for Appropriate Care of the Spine-Injured Athlete⁸⁵ both recommend that the helmet with facemask removed and the

TABLE 2
Helmet and Airway Management^a

References	Study Variable	Problems	Conclusions
Godwin et al ⁵³	Evaluate whether football equipment would interfere with ability to intubate by emergency medicine physicians	Abstract only; training manikin; physicians inserting ETT	Endotracheal intubations are difficult and often unsuccessful in athletes wearing protective athletic equipment; recommend alternative means for securing an airway in these athletes
Kleiner and Miller ⁸⁰	Evaluate whether football equipment would interfere with ability to intubate by EMT-P	Abstract only; training manikin; EMT-Ps inserting ETT	Endotracheal intubations are difficult and often unsuccessful in athletes wearing protective athletic equipment; recommend alternative means for securing an airway in these athletes
Kleiner and Miller ⁷⁹	Evaluate whether football equipment would interfere with the ability to secure ETT or ETC by EMT-P	Abstract only; training manikin; EMT-Ps inserting ETT/ETC	ETC can be inserted quicker than ETT in an athlete wearing protective equipment
Kleiner et al ⁹¹	Evaluate whether football equipment would interfere with ability to secure ETC by ATCs	Abstract only; training manikin; ATCs inserting ETC	ETC can be safely inserted in an athlete wearing protective equipment
Kleiner et al ⁸⁸	Evaluate whether football equipment would interfere with ability to secure LMA by ATCs	Abstract only; training manikin; ATCs inserting LMA	LMA can be safely inserted in an athlete wearing protective equipment; ATCs can perform insertion compared to EMT-Ps and physicians
Miller and Kleiner ¹¹³	Evaluate whether football equipment would interfere with ability to secure ETC by EMT-Ps	Abstract only; training manikin; EMT-Ps inserting ETC	ETC can be safely inserted in an athlete wearing protective equipment

^aETT, endotracheal tube; EMT-P, emergency medical technician-paramedic; ETC, esophageal tracheal Combitube; ATC, certified athletic trainer; LMA, laryngeal mask airway.

shoulder pads remain in place during the initial clinical and radiographic assessment in the emergency department. Only after radiographs have been obtained and reviewed should the helmet and shoulder pads be removed in a controlled environment. Standard 3-view imaging provides reliable screening for most patients with blunt trauma.^{1,114,154} However, the protective helmet and shoulder pads worn by athletes may interfere with the adequate visualization that is required for spinal clearance. Proper visualization of the cervical spine by radiographs was not adequate in 2 small studies using normal volunteers, and one would expect radiographs to be more problematic in actual players (Table 5).^{31,176} Protective helmets and shoulder pads have metal and plastic components that interfere with adequate visualization of the cervical spine on screening radiographs. If these components do not allow adequate visualization of the entire cervical spine, the helmet and shoulder pads need to be removed or mechanically altered.

Initial CT evaluation has been recommended in acute cervical spine trauma.^{61,102,134,150} Lateral CT scout films have been used with good success in several research studies,^{99,166} and a study looking at the feasibility of CT scanning in the initial workup of the helmeted athlete has

shown that CT films with helmet and shoulder pads in place were adequate for initial diagnosis and triage.¹⁸⁵ An MRI of acute spinal cord injury in the unhelmeted patient provides excellent visualization of neurologic and soft tissue structures.¹⁵⁶ Two studies used MRI in protocols to study spinal cord diameters in helmeted athletes, but all metallic pieces were removed from the helmet before the scans, and special custom-made shoulder pads with no metal components were used.^{168,169} With present-day football helmets, the amount and type of metal within the helmet results in sufficient field inhomogeneity and skew artifact to preclude adequate evaluation of the cervical structures, rendering MRI evaluation in this setting clinically limited.¹⁸⁶ The replacement of ferromagnetic components in the helmet with MRI-compatible materials by the manufacturers would be required to perform adequate imaging in these patients using present-day MRI technology. If adequate visualization of the cervical spine is not obtained by radiographs with equipment in place, initial triage may be justified to bypass radiographs and go directly to CT evaluation in these high-risk patients with protective gear in place.¹⁸⁰ If immediate CT scanning is not available, then equipment may need to be removed in the emergency department before radiographic clearance.

TABLE 3
Helmet and Shoulder Pad Removal
(at least a 2-person procedure)¹²⁴

1. Person A is positioned at the top of the patient's head and manually stabilizes the head and neck by placing an arm on each side of the patient's head. The hands of person A, with thumbs pointing up, stabilize the patient's head.
2. Person B removes the facemask if it has not already been removed.
3. Person B removes the chin strap by cutting or unsnapping it.
4. Person B removes the cheek/jaw pads from the helmet by slipping the flat blade of a screwdriver or bandage scissor between the pad snaps and the helmet's inner surface and twisting slightly. Pull firmly and slowly to slide the pad out. Remove the pad on the other side in the same way. Note that the design of the Riddell Revolution helmet does not allow helmet removal with removal of the traditional jaw pads.¹⁶⁴ Jaw pads cannot be removed in this helmet. The jaw pads need to be deflated by puncture with an 18-gauge needle before removal. This is an important distinction regarding the Riddell Revolution helmet.
5. Person B deflates the air inflation system by releasing air at the external ports with an open inflation needle (18-gauge or air pump needle). Most helmets have internal air pockets that secure the helmet tightly against the head. These inflated pockets must be deflated before helmet removal. The inflation needle will remove the air. If an inflation needle is not available, the bladder can be broken and depressed with an 18-gauge needle.
6. Person B takes over in-line immobilization of the head. With 1 hand, person B grasps the patient's mandible between the thumb and first 2 fingers while placing the other hand under the occiput. Person A places a thumb inside each ear hole of the helmet and curls the fingers along the bottom edge of the helmet. Some authors suggest that the helmet can be spread and eased off by pulling laterally and longitudinally in line with the head and neck.¹²⁴ However, it has been suggested that this maneuver serves to tighten the helmet at the occiput and the forehead.³ The task force has recommended that the helmet be rotated off the head in a gentle fashion without pulling laterally.⁸⁵
7. The external shirt should be cut immediately on arrival to provide optimal exposure. The shoulder pads are removed by cutting the straps underneath the arms and the anterior straps holding the pads together. If a neck roll or roll restriction pad is present, it should be unfastened from the helmet and shoulder pads before removal. The shoulder pads and helmet should be removed simultaneously to prevent the head from falling into extension. If the shoulder pads cannot be removed simultaneously, the head must be stabilized in a neutral position during this procedure. The hands of person B can be moved superiorly as the helmet is being removed so that the thumb and first fingers grasp the maxilla at each side of the nose in the maxillary notch.
8. If the helmet cannot be removed and access to the chest area is required, the anterior half of the shoulder pads can be removed, leaving the posterior portion to maintain cervical position with the helmet in place.
9. A cervical collar can be placed after helmet removal, and in-line stabilization can be maintained.

TABLE 4
Facemask Removal From a Football Helmet

1. Maintain neutral position of the head and neck.
2. Remove the athlete's mouthpiece.
3. Maintain the chin strap and helmet cheek pads in place.
4. Cut through the 4 clips fastening the facemask to the helmet.
5. One member removes the facemask while another maintains head and neck stabilization.
6. Carefully clear the facemask of the clips, being especially cautious of any anterior remnants and extraneous cervical spine motion. Remove the facemask completely if possible.^{82,122}

Helmet/Equipment Design and Backboard Immobilization

Football helmet design differs from that of other helmets (Figure 5).^{15,71} The helmeted athlete with a potential cervical spine injury should be properly immobilized on a backboard, with the helmet taped to the backboard and facemask removed.^{76,153} Stabilization of the helmet will limit movement of the head within the helmet, which is necessary for spinal immobilization.^{76,184} Some investigators have questioned whether immobilization of loosely fitted helmets, such as those worn in hockey, will actually limit the amount of head movement within the helmet.¹²⁶ The movement within a properly stabilized lacrosse, ice hockey, or football helmet has been shown to be minimal, although the actual amount of movement that is safe has not been established.¹⁸⁴ The safety and emergency treatment protocols of helmets depend on proper equipment fitting, and clinicians should be aware that poorly fitting equipment might affect in-line immobilization techniques.¹ The National Athletic Trainers' Association protocol for helmet and shoulder pads removal (Table 3) has been shown to effectively limit motion of the cervical spine during equipment removal.¹²⁹

Because of neck hyperextension, helmet removal should be delayed until both the helmet and shoulder pads can be removed together.^{42,123,132,153,166} Although it has been suggested that a hard collar be placed around the helmeted neck during transport,^{111,131,177} achieving proper fit for cervical collars in these helmeted athletes is often difficult because the helmet and shoulder pads with attached neck roll/collar may interfere with proper positioning of the collar.¹⁸⁰ In a study of cervical spine movement in asymptomatic helmeted football, lacrosse, and ice hockey players, cervical collars could not be properly placed because of other equipment restraints (Figure 6).¹⁸⁴ This finding was recognized by the Inter-Association Task Force for Appropriate Care of the Spine-Injured Athlete in its statement that the potentially injured helmeted spine can be stabilized with helmet and shoulder pads without a collar.⁸⁵ Proper immobilization with commercially available

¹References 52, 62, 105-107, 125, 126, 147.

TABLE 5
Radiography as Screening

References	Subjects	Methods	Number of Subjects	Techniques	Limitations	Results	Recommendations
Davidson et al ¹³¹	Male volunteers	Radiographs	N = 20	2-view radiograph series with and without football helmet and pads	2-film series, football only	Poor visualization of C1-C3, C6-C7, C7-T1 interspace with helmet and pads	Guidelines for helmet and pads removal are needed before radiographs; helmet and shoulder pads are impediments to radiographic visualization
Veenema et al ¹⁷⁶	Male volunteer	Radiographs	N = 1	Lateral scout film with no equipment; football and hockey helmets and pads	1-film only, football and hockey	Radiographs (football) inadequate; radiographs (hockey) C7, C7-T1 inadequate	Football helmets should be removed before radiographs; hockey films may be adequate if C7, C7-T1 can be visualized
Waninger et al ¹⁸⁶	Male volunteer	MRI	N = 1	MRI with helmet and shoulder pads in place	Abstract only; equipment fitted by managers	MRI films had sufficient field inhomogeneity and skew artifact to preclude adequate evaluation of the cervical structures	MRI plays only a limited role in the initial evaluation of the neck-injured helmeted athlete, with present-day MRI capability and equipment
Waninger et al ¹⁸⁵	Male volunteers	CT	N = 5	CT with and without helmet and shoulder pads on	Abstract only; equipment fitted by managers	Quality of CT scans was adequate for evaluation of cervical spine structures	CT scans may play an important role in the initial evaluation of the neck-injured helmeted athlete

specialized binders (Figure 6),¹⁸⁴ sandbags,^{111,182} and taping^{131,157} can be used. Although sandbags have lost favor in the prehospital management of unhelmeted trauma victims,¹⁵⁷ the weight and shape of the helmet may require greater stabilization to prevent lateral movement of the head and neck.¹⁸³ Sandbag placement for lateral cervical spine stabilization has been recommended to help secure the helmet in injured hockey players.¹¹¹ Lightweight foam pads or rolled-up towels may not be adequate alone for stabilization in the helmeted athlete.⁴⁹ If available, commercial backboards with specialized binders that firmly secure the helmet and neck may be the optimal choice of backboard immobilization (Figure 6).¹⁸⁴ A specialized cervical spine immobilizer that limits spinal range of motion while the helmeted athlete is immobilized and transported has been studied but is not in general use.¹³⁸

Shoulder pads with helmet in place elevate the torso to maintain a relatively neutral cervical spine position.^{42,109,153,166} Unacceptable cervical motion can occur during motorcycle helmet removal if the shoulders are not properly elevated.¹¹² Both American football and ice hockey players wear protective shoulder pads as part of their standard equipment. The shoulder pads in football are larger in design and often include an attached collar roll to prevent neck hyperextension and rotational/lateral

bending (Figure 7). No single piece of protective equipment will appreciably alter flexion, and attempts to alter shoulder pads and helmet design to prevent extremes of flexion have been studied with some success but are not in common use today.⁸ In the transport of an athlete with a potential cervical spine injury, proper immobilization includes leaving both the helmet and shoulder pads in place.^{35,42,152,153} Emergency medical service providers must take into account the method of removal of a player off the field because standard emergency medical service immobilization equipment may be inadequate for the large size of the athlete.¹³⁶ The location of rescue vehicles for transport and the safety of methods to transport the athlete to the rescue vehicle are all issues that need to be further discussed.⁷ The contribution of shoulder pads to the mechanism of cervical spine injury in other sports such as lacrosse and rugby has not been well studied.¹³⁵

Facemask Removal

It is recommended that all facemasks be removed (Table 4) from football helmets (Figure 5A) before transport, regardless of current respiratory status. When facemask removal is required, the plastic clips attaching the facemask are cut. Safe techniques for facemask removal are well



Figure 5. Examples of (A) football, (B) ice hockey, (C) lacrosse, and (D) motorcycle helmets.

described.^{35,83,94,140} With practice, the facemask of any helmet can be quickly and safely removed with minimal risk of extraneous movement of the cervical spine.⁸⁶

There have been many tools (Figure 8) and methods (Table 6) studied for facemask removal.¹⁴³ The proper equipment to remove the facemask should be readily available, and the choice of equipment is less important than the expertise of the personnel with a particular tool⁶⁸ (Table 7). Practice increases skills of facemask removal.⁸⁶ The new Riddell Revolution helmets have a new facemask clip design that cannot be cut using conventional measures and requires a screwdriver for removal (Figure 9E).¹⁶⁴ Consequently, athletic training and medical staff need to be familiar with the equipment used by the players under their care. A quick-release system that eliminates the need for any tools may be available in the future.¹⁴³

Note that ice hockey (Figure 5B) and lacrosse (Figure 5C) facemasks differ from football facemasks in that they

consist of metal bars attached by screws to the superior aspect of the helmet. A plastic or cloth clip attaches the facemask to the helmet and must be cut to gain access to the facial structures. The facemask flips up easily but remains attached to the helmet by metal screws. Often, these helmets have rusted hardware that makes removal difficult. There are no established guidelines for removal of facemasks in ice hockey and lacrosse,²⁵ although removal with a screwdriver may be the preferred method if the screws are well maintained and not rusted. Metal cutters may be used to cut the facemask, but this maneuver may cause unacceptable torque and movement.

Helmet and Shoulder Pad Removal

The recommendation of both the NCAA¹¹⁷ and the Inter-Association Task Force for Appropriate Care of the Spine-Injured Athlete⁸⁵ is that only after radiographs have been

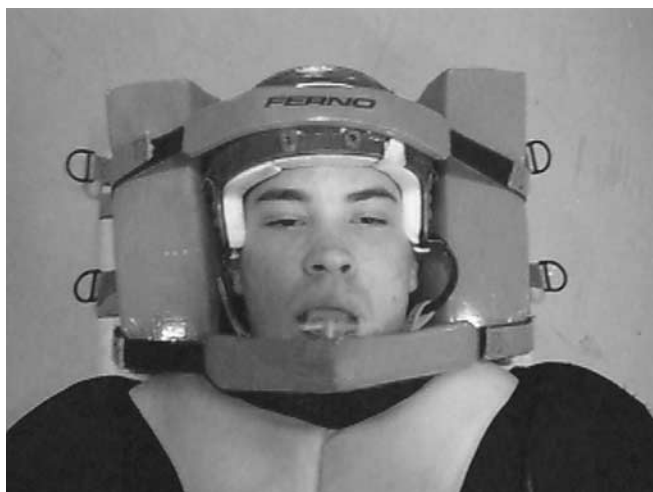

Figure 6. An ice hockey player immobilized on commercial backboards with specialized binders that firmly secure the helmet and neck.¹⁸⁴ This may be the optimal choice of backboard immobilization in helmeted athletes. Mouthpieces should routinely be removed before transport. (Reprinted with permission, Waninger et al.¹⁸⁴)



Figure 7. Football player with shoulder pads, neck collar roll in place (arrow). (Reprinted with permission, Lehigh University, 2002.)

obtained and reviewed should the helmet and shoulder pads be removed. Equipment should be removed only by qualified trained medical personnel. These recommendations reflect the belief that maintaining spinal immobilization during removal of the football helmet and shoulder pads is quite difficult and requires training, practice, and multiple qualified personnel.¹⁸⁰



Figure 8. Helmet removal tools. A, facemask extractor; B, PVC pipe cutter; C, Trainer's Angel; D, wire cutter; E, electric screwdriver; F, manual screwdriver; G, reflex hammer (used to pry away cheek pads); H, air pump needle (used to deflate the helmet air bladder). (Anvil pruner and 18-gauge needle not pictured.)

Current guidelines on equipment removal represent a consensus of those with clinical expertise in the field rather than evidence-based medicine. The athlete should be stabilized on a backboard, facemask removed, with helmet and shoulder pads in place. If the athlete is face down or side lying, he/she should be moved into place as a unit via a coordinated logroll technique. The decision to remove an athlete's equipment has been guided by the "all or nothing" principle: if it is determined that either the helmet or shoulder pads need to be removed, they both should be removed simultaneously. Simultaneous helmet and shoulder pad removal may be warranted in the following situations^{35,92,124,153}:

1. The helmet is so loose that adequate spinal immobilization cannot be obtained with the helmet in place; that is, the helmet and chin strap do not hold the head securely.
2. The design of the helmet and chin strap is such that even after removal of the facemask, the airway cannot be assessed or managed properly.
3. The facemask or visor interferes with adequate airway management, and the facemask cannot be removed after a reasonable period of time.
4. The helmet prevents immobilization for transport.
5. There is evidence of a head injury requiring direct inspection.
6. The patient has arrived at the emergency department, and initial radiographs or CT scans are normal or nondiagnostic.

Studies show that proper immobilization of football, ice hockey, and lacrosse helmets does prevent movement of

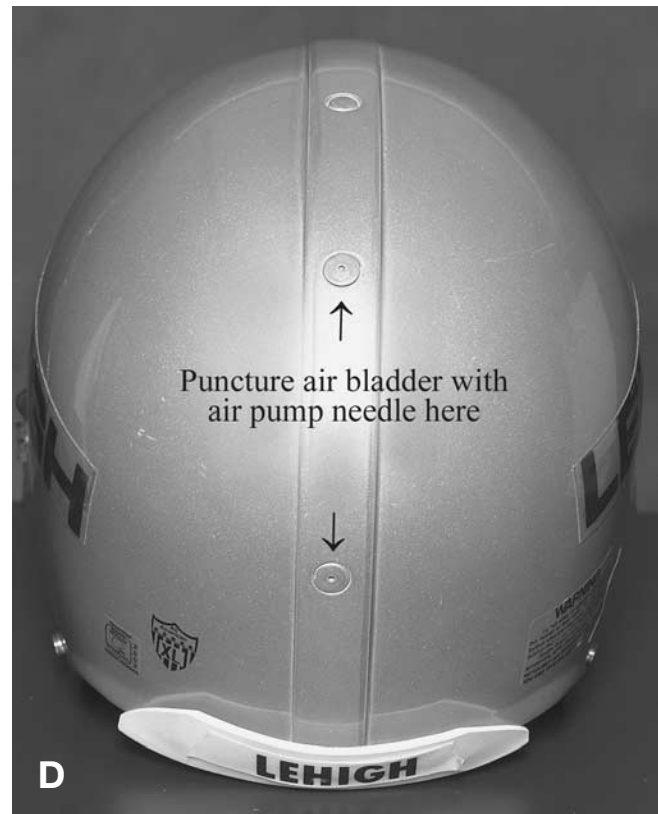
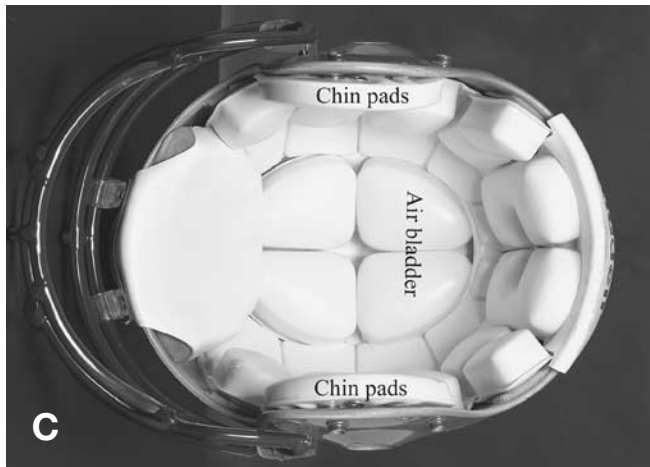
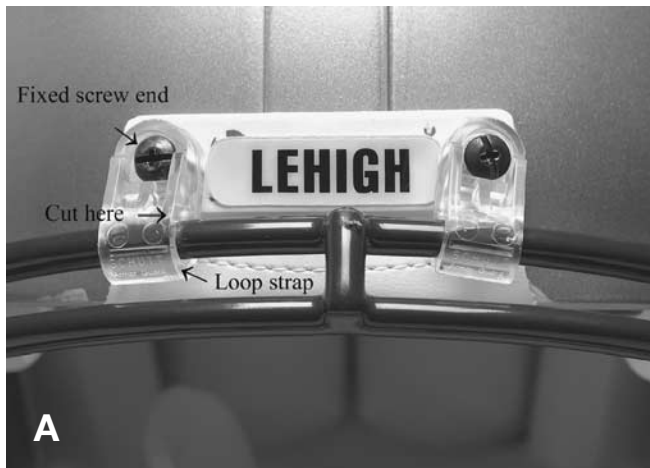


Figure 9. Football helmet. Anterior view (A) and side view (B) of facemask loop straps that attach the facemask to the helmet (area to cut for quick removal indicated). The helmet cheek or jaw pads (C, labeled “chin pads”) can be removed by gently prying the pads loose from their snap attachments with a reflex hammer handle or similar tool and then sliding the pads out. If the helmet has an internal air pad (C), it should be deflated by tapping it with an air pump needle or an 18-gauge needle before helmet removal, as diagrammed in D. The new Riddell helmet has a clip design that cannot be cut off but requires the clip to be removed by a screwdriver (E). It also has cheek pads that are not removable and that require a puncture with an 18-gauge needle to facilitate helmet removal.

TABLE 6
Facemask Studies for American Football Helmets^a

References	Study Variable	Tools	Problems	Conclusions
Almquist et al ⁵	Response time	TA, AP, PVC, SD	Abstract only	Carrying tools for facemask removal improves response time
Angotti et al ⁹	Time needed to cut facemask straps using 3 techniques	FME	Abstract only	FME has 3 technique options for facemask removal
Block et al ¹⁶	Time needed to cut facemask straps and retract mask	TA, AP	Abstract only; student ATCs	Differences in amount of time and amount of movement with different tools and facemask straps
Brown et al ²⁰	Hand placement patterns of removal tools	TA, AP, FME, PVC	Abstract only	Various hand positions are used during helmet removal; FME and AP allowed subjects to perform removal with 1 hand
Ensch et al ⁴⁰	Evaluate whether transfer of learning occurs with respect to time needed to cut facemask straps and retract facemask	FME, TA, AP	Abstract only; subjects had no prior experience in face-mask removal	Practicing a specific tool improves performance with tool, but improvement will not transfer to other tools
Fuchs et al ⁴⁸	Time needed to cut facemask straps and retract mask	AP, PSD, TA, SD	Abstract only	Differences in amount of time and amount of movement with different tools and facemask straps
Hall et al ⁶⁰	Time needed to cut facemask straps and retract mask	FME, TA, PVC, AP	Abstract only	FME most effective; FME and TA required fewest number of cuts to remove facemask
Hoenshel et al ⁶⁷	Time needed to cut facemask straps and retract mask	FME, TA, AP	Abstract only	Greater satisfaction with FME, AP faster than FME or TA
Hoenshel et al ⁶⁸	Evaluation of 3 methods of FME use	FME	Abstract only	Recommend use of tool technique that is most practiced and at which trainers have most skill
Jenkins et al ⁷⁵	Time and torque needed to cut facemask straps and retract mask measured via force platform	FME, TA, PSD, QRS		Removal of plastic clips via QRS or PSD faster with less force and torque than TA or FME
Kleiner et al ⁸⁶	Time needed to cut facemask straps and retract mask	TA, AP	Abstract only	Practice decreases time and increases efficiency of facemask removal
Kleiner ⁸²	Facemask removal vs retraction, amount of movement of spine	TA, AP	AP more effective than TA cutting straps, satisfaction	Complete extraction of face mask vs retraction results in less extraneous cervical spine movement; recommend to practice skill of facemask removal
Kleiner and Knox ⁹⁰	Facemask removal techniques	TA, KN, SD, other	Abstract only; survey	Recommend practice skill of facemask removal; suggest skill be made ATC competency requirement
Kleiner and Greenwood ⁸⁹	Hand size and grip strength	TA, AP	Abstract only; healthy controls	Unable to attribute differences in male and female study subjects to hand size or grip strength
Kleiner and Knox ⁹⁰	Evaluate technique with TA	TA	Abstract only; healthy controls; observational study, not well controlled	The skill of facemask removal should be included as a competency requirement for ATCs
Kleiner and Sonnenberg ⁹³	Temperature	TA, AP	Abstract only; healthy controls	Differences in time and satisfaction related to temperature; increased difficulty in facemask removal in cold environments

(continued)

TABLE 6
Continued

References	Study Variable	Tools	Problems	Conclusions
Knox and Kleiner ⁹⁷	Qualifications; satisfaction; efficiency with tools; time to removal; amount of head movement	SD, TA, AP, KN	KN removed because of causing injury to staff; healthy controls	No difference in time; movement highest with TA; satisfaction greatest with AP; ATCs need to practice skill of facemask removal
Knox and Kleiner ⁹⁶	Comparison of time to remove and retract facemask using S	S	Abstract only; healthy controls; ATCs and EMTs served as subjects	EMT shears are not the ideal tools to remove facemasks
O'Sullivan et al ¹²²	Comparison of time to remove vs retract facemask	FME, TA, PVC, AP	Abstract only; healthy controls	Removal faster than retraction for all tools; supports removal of facemasks; removal time for PVC longest
Pearson et al ¹²⁷	Facemask removal time	PVC, AP	Abstract only; healthy controls	No gender differences, but significant differences dependent on experience; AP faster than PVC
Pearson et al ¹²⁸	Ease and speed of removal of 2 brands of facemask loop straps	TA, AP	Abstract only; healthy controls	Loop straps are made of different consistencies; tool efficiency differs with loop-strap brands
Putnam ¹³³	Feasibility of alternative facemask removal tools	PSD, SD, WC	Demonstration, not real study	Several alternative methods are available for facemask removal; bolt cutters needed for older facemasks
Ray et al ¹⁴⁰	Cervical spine motion measured via video motion analysis	PM, SD	Healthy controls	PM insertion techniques allow quicker insertion and initiation of rescue breathing; cervical spine displacement not significant; PM can be used without facemask removal
Ray et al ¹⁴¹	Qualifications; efficiency with tools; time to removal; amount of head movement	SD, PSD, TA, PM	Healthy controls	PM insertion techniques allow quicker insertion and initiation of rescue breathing; TA more extraneous motion; PM can be used without facemask removal
Redden et al ¹⁴²	Gender and grip strength on time needed to cut facemask straps	TA, AP	Abstract only; healthy controls	Differences in time to cut and in satisfaction between TA and AP
Sanville et al ¹⁴⁸	Age (sharpness) of the removal tools	TA, AP	Abstract only; healthy controls	AP preferred over TA; both less effective when dull compared to sharp
Surace et al ¹⁶²	Facemask removal time and head motion during removal	AP, TA, SD	Abstract only; healthy controls	SD most effective, less head motion
Swartz et al ¹⁶³	Facemask removal time and head motion during removal using video motion analysis	AP, TA, PVC, FME	Healthy controls	AP quickest; FME least amount of movement
Swartz et al ¹⁶⁵	Facemask removal time and head motion during removal using video motion analysis	AP, TA, PVC, FME	Healthy controls	FME increased performance in time, satisfaction, rating, efficiency; FME increased amount of movement but needs further study
Zeal et al ¹⁹²	Facemask removal time and satisfaction using various loop straps (single, double)	AP, TA, FME	Healthy controls	Modifying the standard single loop straps adversely affects the ability to remove facemask

^aTA, Trainer's Angel; AP, anvil pruner; PVC, polyvinyl chloride pipe cutters; SD, manual screwdriver; FME, facemask extractor tool; ATC, certified athletic trainer; PSD, power screwdriver; QRS, quick-release system; KN, utility knife; S, emergency medical technician scissors/shears; WC, wire cutters; PM, pocket mask insertion technique.

TABLE 7
Helmet Tool Removal Comparisons

Tool	Positives	Negatives
Quick-Release system	Easy system with minimal practice; no tools involved; user-friendly	Still in testing phase, not available; testing on prototype only, new versions not well studied
Facemaks Extractor	Ability to resist slipping while requiring minimal grip strength	High cost; ergonomics often require 2-handed procedure; testing on prototype only; new versions not well studied
Trainer's Angel	One sharp edge; cuts by squeezing the clip between the sharp edge and the opposing buttress	May have problems with hard clips; medium cost
Anvil pruner	Ratchet mechanism best model; may cut harder clips; easy availability; low cost	May have slipping problems with some helmet clips
Electric screwdrivers	Battery-powered units are convenient; user-friendly; less movement; faster times; remove entire clip instead of cutting	Require continuous maintenance to combat screw damage and rust; not reliable; high failure rate
Manual screwdrivers	Easy availability; user-friendly; less movement; faster times; remove entire clip instead of cutting	May cause torque; require continuous maintenance to combat screw damage and rust; not reliable; high failure rate
PVC pipe cutters	Easy availability; low cost	May have problems with hard clips
Bolt cutters	Cut facemask or clips ^{11,47,141} ; needed for older facemasks that attach directly to helmet without clips	torque/rebound effect; not recommended
High-speed rotary tool (with metal cutting blades)	Effective in cutting thicker facemask fastening systems found on lacrosse and hockey helmets; battery-powered units are convenient	Not recommended; may throw shavings into face; may melt plastic clips; bad odor; load noise; need to monitor battery power
Emergency medical technician scissors	Easy availability; low cost	Not effective; not recommended
Utility knife	Easy availability; low cost	Dangerous to user; not effective; not recommended

the head inside the immobilized helmet.¹⁸⁴ However, if the equipment is a liability during immobilization or radiographic evaluation, it must be removed. The shape of the human head and the design of a football helmet allow for a tight custom fit. The head is shaped like a cone, widest at the crown and narrow toward the chin. The helmet, on the other hand, is nearly spherical. Pads are used to secure the helmet tightly at the player's cheekbones, and an air bladder is inflated within the helmet to fill any remaining space. In preparation for helmet removal, the pads need to be removed, and the air bladder needs to be deflated. Holes in the helmet at the ears allow examination of the ears without helmet removal. It is recommended that the chin strap not be removed during transport until the helmet is ready to be removed (Table 4).^{30,85,181} The procedure for removal of helmet and shoulder pads is at least a 2-person process (Table 8).^{103,124} An alternative method of motorcycle helmet removal by bivalving the helmet in the coronal plane has been investigated in a cadaveric model,¹⁰ but no

studies looking at alternate methods of football helmet removal have been examined (see Appendix 6 for helmet studies of interest, available in the online version of this article at www.ajsm.org).

CONCLUSIONS

The approach to the neck-injured player on the field has been well reviewed, and conservative, literature-based algorithms for on-field sideline evaluations of neck pain have been published.⁵⁹ The unique characteristics of the well-fitted football helmet allow safe access to airway management, and helmets and shoulder pads should not be removed in the prehospital management of the football player with a potential cervical spine injury unless absolutely necessary. Prehospital and emergency department personnel must be trained in the proper removal of the football helmet, shoulder pads, and facemask. If required, both helmet and shoulder pads should be

TABLE 8
Guidelines of the Inter-Association Task Force for
Appropriate Care of the Spine-Injured Athlete^{84,85}

General guidelines

1. Manage the athlete suspected of having a spinal injury as though a spinal injury exists.
2. Activate emergency medical service.
3. Assess the athlete's airway, breathing and circulation, neurologic status, and level of consciousness.
4. Do not move the athlete unless absolutely essential to maintain airway, breathing, and circulation.
5. If the athlete must be moved to maintain airway, breathing, and circulation, place him/her in a supine position while maintaining spinal immobilization.
6. When moving a suspected spine-injured athlete, move the head and trunk as a unit (an accepted technique is to manually splint the head to the trunk).

Facemask removal

1. Remove the facemask before transport, regardless of current respiratory status.
2. Have the tools for facemask removal readily available.

Football helmet removal

Remove the athletic helmet and chin strap only . . .

1. If the helmet and chin strap do not hold the head securely, such that immobilization of the helmet does not also immobilize the head.
2. If the helmet and chin strap design prevent airway control or the provision of ventilation even after removal of the facemask.
3. If the facemask cannot be removed after a reasonable period of time.
4. If the helmet prevents immobilization in an appropriate position for transport.

Helmet removal

Maintain spinal immobilization while removing the helmet.

1. Helmet removal should be practiced frequently under proper supervision.
2. In most circumstances, it may prove helpful to remove cheek padding and/or deflate air padding before helmet removal.

Equipment

Maintain appropriate spinal alignment.

1. The helmet and shoulder pads elevate an athlete's trunk when in the supine position.
2. Should either the helmet or shoulder pads be removed or if only 1 is present, appropriate spinal alignment must be maintained.
3. Open the front of the shoulder pads to allow access for cardiopulmonary resuscitation and defibrillation.

removed simultaneously. The strength of the evidence is relatively circumstantial and somewhat anecdotal, but the few related studies have shown that there may be a risk to helmet removal. However, no injuries have been reported from the policy of keeping the equipment in place. In this clinical scenario, it is best to do no harm. There is a need

for greater communication between sports medicine and local emergency providers regarding management of the helmeted athlete. Prehospital and sports medicine teams should formulate a plan in advance to prepare for unexpected clinical scenarios such as cervical spine injuries,⁷ and skills such as facemask and helmet removal should be practiced. All health care specialties that treat these injuries need to be aware of the guidelines for managing helmeted athletes.⁵⁶ Whether these thoughts can be extrapolated to other helmet designs has yet to be established.

If, with equipment in place, adequate radiographic visualization of the cervical spine is not possible, then existing protocols that recommend initial radiographs in these patients may need to be revised. Initial triage may be justified to bypass radiographs and go directly to CT evaluation. If immediate CT scanning is not available, then equipment may need to be removed in the emergency department before radiographic clearance. The MRI presently plays a limited role in the initial clearance of the injured spine before equipment removal. Because this is the standard of care, emergency department personnel should become familiar with helmet and shoulder pad removal procedures.

Some studies advocate helmet removal without differentiating among types of helmets.^{50,58,78} Adequate data evaluating lacrosse, equestrian, baseball/softball, kayak, or bicycle helmets are not available, and results from studies evaluating motorcycle, ice hockey, and football helmets may not be applicable to other helmet designs. Organized football programs requiring helmets as part of the standard equipment also involve the pediatric and female populations. These conclusions, based on studies performed on college-aged male athletes, cannot necessarily be extrapolated to a younger or female population without further study.^{29,66,120}

ACKNOWLEDGMENT

The author thanks the Library Staff and the Media Productions Department at Saint Luke's Hospital for their assistance; Michael Heller, MD, for his guidance in the preparation; and Douglas Kleiner, ATC, PhD, and Joseph Torg, MD, for their review of this article.

REFERENCES

1. *Advanced Trauma Life Support for Doctors*. American College of Surgeons, Committee on Trauma. Chicago: American College of Surgeons; 1997.
2. Allen K. Lions' Brown bruises spine. *USA Today*. December 22-23, 1997.
3. Almquist JL. Spine injury management: a comprehensive plan for managing the cervical spine-injured football player. *Sports Med Update*. 1998;13:8-11.
4. Almquist JL, Kleiner DM. A survey of the techniques to be employed for the on-the-field management of a football player with a suspected spine injury [abstract]. *J Athl Train*. 2002;37(suppl 2):S85-S86.
5. Almquist JL, Rehberg RS, Kleiner DM. An assessment of the response time prior to facemask removal [abstract]. *J Athl Train*. 2000;35(suppl 2):S61.

6. Anderson C. Neck injuries: backboard, bench, or return to play? *Phys Sportsmed*. August 1993;21:23-34.
7. Anderson JC, Courson RW, Kleiner DM, et al. National Athletic Trainers' Association position statement: emergency planning in athletics. *J Athl Train*. 2002;37:99-104.
8. Andrich JT, Bergfeld JA, Romo LR. A method for the management of cervical spine injuries in football: a preliminary report. *Am J Sports Med*. 1977;5:89-92.
9. Angotti DD, Hoenshel RW, Kleiner DM. The most efficient technique for using the FM extractor [abstract]. *J Athl Train*. 2000;35(suppl 2):S60.
10. Aprahamian C, Thompson BM, Darin JC. Recommended helmet removal techniques in a cervical spine injured patient. *J Trauma*. 1984;24:841-842.
11. Bailes JE, Maroon JC. Management of cervical spine injuries in athletes. *Clin Sports Med*. 1989;8:43-57.
12. Benson BW, Mohtadi NGH, Rose MS, et al. Head and neck injuries among ice hockey players wearing full face shields vs half face shields. *JAMA*. 1999;282:2328-2332.
13. Berge J, Marque B, Vital JM, et al. Age-related changes in the cervical spines of front-line rugby players. *Am J Sports Med*. 1999;27:422-429.
14. Bishop PJ. Factors related to quadriplegia in football and the implications for interventional strategies. *Am J Sports Med*. 1996;24:235-239.
15. Bishop PJ, Norman RW, Kozey JW. An evaluation of football helmets under impact conditions. *Am J Sports Med*. 1984;12:233-236.
16. Block JJ, Kleiner DM, Knox KE. Football helmet facemask removal with various tools and straps [abstract]. *J Athl Train*. 1996;31(suppl 2):S11.
17. Bond GR, Christoph RA, Rodgers BM. Pediatric equestrian injuries: assessing the impact of helmet use. *Pediatrics*. 1995;95:487-489.
18. Brandenburg MA, Archer P. Survey analysis to access the effectiveness of the bull touch helmet in preventing head injuries in bull riders: a pilot study. *Clin J Sport Med*. 2002;12:360-366.
19. Branfoot T. Motorcyclists, full-face helmets, and neck injuries: can you take the helmet off safely, and if so, how? *J Accid Emerg Med*. 1994;11:117-120.
20. Brown A, Armstrong CW, Rankin J, et al. Observed hand placement patterns of certified trainers while using various facemask removal tools [abstract]. *J Athl Train*. 2001;36(suppl 2):S69.
21. Budassi SA. Helmet removal from injured patients. *J Emerg Nurs*. 1981;7:290.
22. Burney RE, Waggoner R, Maynard FM. Stabilization of spinal injury for early transfer. *J Trauma*. 1989;29:1497-1499.
23. Caro DA, Kleiner DM. Athletic spine injuries, emergency medicine physicians, and video training [abstract]. *J Athl Train*. 2002;37(suppl 2):S85.
24. Casazza BA, Rossner K. Baseball/lacrosse injuries. *Phys Med Rehabil Clin N Am*. 1999;10:141-157.
25. Caswell SV, Deivert RG. Lacrosse helmet designs and the effects of impact force. *J Athl Train*. 2002;37:164-171.
26. Ching RP, Thompson DC, Thompson RS, et al. *Damage to bicycle helmets involved with crashes*. *Accid Anal Prev*. 1997;29:555-562.
27. Committee on Sports Medicine and Fitness. Safety in youth ice hockey: the effects of body checking (RE9835). *Pediatrics*. 2000;105:657-658.
28. Coon ME, Chan SB. Investigation into the relationship between intracranial injury and cervical spine injury in pediatric sports trauma [abstract]. *Ann Emerg Med*. 2003;42:S87.
29. Curran C, Dietrich AM, Bowman MJ, et al. Pediatric cervical spine immobilization: achieving neutral position? *J Trauma*. 1995;39:729-732.
30. Dansen KR. On-field management of the injured football player [letter to the editor]. *Clin J Sport Med*. 2000;10:82-83.
31. Davidson RM, Burton JH, Snowise M, et al. Football protective gear and cervical spine imaging. *Ann Emerg Med*. 2001;38:26-30.
32. Davis JW, Phreaner DL, Hoyt DB, et al. The etiology of missed cervical spine injuries. *J Trauma*. 1993;34:342-346.
33. DeLorenzo RA, Olson JE, Boska M, et al. Optimal positioning for cervical immobilization. *Ann Emerg Med*. 1996;28:301-308.
34. Del Rossi G, Horodyski M, Powers ME. A comparison of spine-board transfer techniques and the effect of training on performance. *J Athl Train*. 2002;38:204-208.
35. Denegar C, Saliba E. On the field management of the potential cervical spine injured football player. *J Athl Train*. 1989;24:108-111.
36. Domeier RM, Evans RA, Swor RA, et al. Prehospital clinical findings associated with spinal injury. *Prehosp Emerg Care*. 1997;1:11-15.
37. Domeier RM, Evans RA, Swor RA, et al. Prospective validation of prehospital spinal clearance criteria. *Acad Emerg Med*. 1997;6:643-646.
38. Donaldson WF, Lauerman WC, Heil B, et al. Helmet and shoulder pad removal from a player with suspected cervical spine injury: a cadaveric model. *Spine*. 1998;23:1729-1733.
39. Ducker TB, Salzman M, Daniell HB. Experimental spinal cord trauma, III: therapeutic effect of immobilization and pharmacological agents. *Surg Neurol*. 1978;10:71-76.
40. Ensch CA, Kleiner DM, Tillman MD. The effect of tool familiarity on facemask removal [abstract]. *J Athl Train*. 2001;36(suppl 2):S68.
41. Feld F. Management of the critically injured football player. *J Athl Train*. 1993;28:206-212.
42. Feld F, Blanc R. Immobilizing the spine injured football player. *J Emerg Med Serv*. 1987;12:38-40.
43. Finch CF, McIntosh AS, McCrory PM. What do under 15-year-old schoolboy rugby union players think about protective headgear? *Br J Sports Med*. 2001;35:89-94.
44. Fine KM, Vegso JJ, Sennett B, Torg JS. Prevention of cervical spine injuries in football: a model for other sports. *Phys Sportsmed*. October 1991;19:54-63.
45. Fischer MP, Rehberg RS, Kleiner DM, et al. Attention about football equipment removal of procedures from EMT-B students [abstract]. *J Athl Train*. 2002;37(suppl 2):S85.
46. Fischer RP. Cervical radiographic evaluation of alert patients following blunt trauma. *Ann Emerg Med*. 1984;13:905-907.
47. Fourre M. On-site management of cervical spine injuries. *Phys Sportsmed*. April 1991;19:53-56.
48. Fuchs EJ, Haug CH, Bryant JE, et al. Facemask removal time of four facemask extrication devices [abstract]. *J Athl Train*. 1996;31(suppl 2):S38.
49. Funk FJ, Wells RE. Injuries of the cervical spine in football. *Clin Orthop*. 1975;109:50-58.
50. Gallup DA, Boker JR, Hartz L. Helmet types and removal. *Emerg Med Serv*. 1981;10:91-92.
51. Gastel JA, Palumbo MA, Hulstyn MJ, et al. Emergency removal of football equipment: a cadaveric cervical spine injury model. *Ann Emerg Med*. 1998;32:411-417.
52. Gieck J, McCue FC. Fitting of protective football equipment. *Am J Sports Med*. 1980;8:192-196.
53. Godwin SA, Kleiner DM, Norton CE. The ability of physicians to perform endotracheal intubation with a football helmet, face mask, and chin strap. 2003 Southeastern Regional Meeting of the Society for Academic Emergency Medicine; April 11-13, 2003; Jacksonville Beach, Fla.
54. Gooding MR, Wilson CB, Hoff JT. Experimental cervical myelopathy: effects of ischemia and compression of the canine spinal cord. *J Neurosurg*. 1975;43:9-17.
55. Gorden JA, Straub SJ, Swanik CB, et al. Effects of football collars on cervical hyperextension and lateral flexion [abstract]. *J Athl Train*. 2001;36(suppl 2):S71.
56. Greenstein JS, Kleiner DM. Guidelines for the pre-hospital management of the spine-injured athlete. *J Sports Chiropract Rehabil*. 2000;14:105-110.
57. Grimard G, Nolan T, Carlin JB. Head injuries in helmeted child bicyclists. *Inj Prev*. 1995;1:21-25.
58. Hafen BQ, Karren KJ. Helmet removal. In: *Prehospital Emergency Care and Crises Intervention*. Englewood Cliffs, NJ: Prentice Hall; 1992:285-288.
59. Haight RR, Shiple BJ. Sideline evaluation of neck pain: when is it time for transport. *Phys Sportsmed*. March 2001;29:45-62.

60. Hall MC, Decoster LC, Norkus SA, et al. Comparison of four popular tools for number of cuts required, correlated with time, and success in first attempt to remove a football facemask [abstract]. *J Athl Train.* 2002;37(suppl 2):S37.
61. Hanson JA, Blackmore CC, Mann FA, et al. Cervical spine injury: a clinical decision rule to identify high-risk patients for helical CT screening. *Am J Roentgenol.* 2000;174:713-717.
62. Hart CM, McGuine TA. Football helmet fitting errors for high school grade levels. *J Athl Train.* 1995;29(suppl 2):S159-S160.
63. Hastings RH, Kelley SD. Neurologic deterioration associated with airway management in a cervical spine-injured patient. *Anesthesiology.* 1993;78:580-583.
64. Heck JF. The incidence of spearing by high school football ball carriers and their tacklers. *J Athl Train.* 1992;27:120-124.
65. Heck JF. The incidence of spearing during a high school's 1975 and 1990 football seasons. *J Athl Train.* 1996;31:31-37.
66. Herzenberg JE, Dedrick DK, Phillips WA. Emergency transport and positioning of young children who have an injury of the cervical spine: the standard backboard may be dangerous. *J Bone Joint Surg Am.* 1989;71:15-22.
67. Hoenshel RW, Angotti DD, Kleiner DM. An objective evaluation of the FM extractor [abstract]. *J Athl Train.* 2000;35(suppl 2):S61.
68. Hoenshel RW, Pearson DB, Kleiner DM. The technique most commonly employed with the FM extractor [abstract]. *J Athl Train.* 2001;36(suppl 2):S70.
69. Hoffman JR, Mower WR, Wolfson AB, et al. Validity of a set of clinical criteria to rule out injury to the cervical spine in patients with blunt trauma. *N Engl J Med.* 2000;343:94-99.
70. Holland AJ, Roy GT, Gob V, et al. Horse-related injuries in children. *Med J Aust.* 2001;175:609-612.
71. Huston RL, Sears J. Effect of protective helmet mass on head and neck dynamics. *J Biomech Eng.* 1981;103:18-23.
72. Irvin WS, Bowman LS. Inconsistencies in the treatment of football neck injuries. *J S C Med Assoc.* 2000;96:345-347.
73. Iselborn AJ, Kleiner DM, Pearson DB. The amount of spine movement that occurs with football helmet removal [abstract]. *J Athl Train.* 2001;36(suppl 2):S72.
74. Jacobs C, Rozea G, Horodyski MB. Football collars increase cervical extension during immobilization [abstract]. *J Athl Train.* 2001;36(suppl 2):S68.
75. Jenkins HL, Valovich TC, Arnold BL, et al. Removal tools are faster and produce less force and torque on the helmet than cutting tools during face-mask retraction. *J Athl Train.* 2002;37:246-251.
76. Jones MD. Cineradiographic studies of the collar-immobilized cervical spine. *J Neurosurg.* 1960;17:633-637.
77. Josefson D. US call for mandatory skiing helmets. *BMJ.* 1998;316:172.
78. Kennedy MA. Athletic trauma [abstract]. *Med Sci Sports Exerc.* 1997;29:S211.
79. Kleiner BM, Miller GL. Endotracheal intubation vs Combitube insertion: implications for athletic protective equipment [abstract]. 2003 Southeastern Regional Meeting of the Society for Academic Emergency Medicine; April 11-13, 2003; Jacksonville Beach, Fla.
80. Kleiner BM, Miller GL. The influence of a football face mask and chin strap on endotracheal intubation [abstract]. *Med Sci Sports Exerc.* 2002;35(suppl 5):S102.
81. Kleiner DM. Attitudes and knowledge about removing athletic protective equipment in the prehospital setting [abstract]. 2002 Southeastern Regional Meeting of the Society for Academic Emergency Medicine; April 12-14, 2002; Jacksonville Beach, Fla.
82. Kleiner DM. Facemask removal vs facemask retraction [abstract]. *J Athl Train.* 1996;31(suppl 2):S32.
83. Kleiner DM. Football helmet facemask removal. *Athletic Ther Today.* 1996;1:11-14.
84. Kleiner DM. Prehospital care of the spine-injured athlete: monograph summary. *Clin J Sport Med.* 2003;13:59-61.
85. Kleiner DM, Almquist JL, Bailes J, et al. *Prehospital Care of the Spine-Injured Athlete: A Document From the Inter-Association Task Force for Appropriate Care of the Spine-Injured Athlete.* Dallas, Texas: National Athletic Trainers' Association; March, 2001.
86. Kleiner DM, Almquist JL, Hoenshel RW, et al. The effects of practice on facemask removal skills [abstract]. *J Athl Train.* 2000;35(suppl 2):S60.
87. Kleiner DM, Bozeman WP, Caro D, et al. Knowledge of football equipment removal guidelines among attendees of a regional emergency medicine meeting [abstract]. 2002 Southeastern Regional Meeting of the Society for Academic Emergency Medicine; April 12-14, 2002; Jacksonville Beach, Fla.
88. Kleiner DM, Godwin SA, Norton CE. Laryngeal mask airway (LMA) insertion and football equipment [abstract]. 2003 Southeastern Regional Meeting of the Society for Academic Emergency Medicine; April 11-13, 2003; Jacksonville Beach, Fla.
89. Kleiner DM, Greenwood LD. The influence of hand size and grip strength on the ability to remove a football helmet facemask [abstract]. *J Athl Train.* 1997;32(suppl 2):S50.
90. Kleiner DM, Knox KE. An evaluation of the techniques used by athletic trainers when removing a facemask with a Trainers Angel [abstract]. *J Athl Train.* 1995;30(suppl 2):S7.
91. Kleiner DM, Pearson DB, Hoenshel RW, et al. Certified athletic trainers, Combitube insertion, and football equipment [abstract]. *J Athl Train.* 2002;37(suppl 2):S38.
92. Kleiner DM, Pollak AN. Dos & don'ts of football helmet removal. *JEMS.* July 2001;26:37-48.
93. Kleiner DM, Sonnenberg RJ. The influence of temperature on the ability to cut the football helmet facemask loop-strap attachment [abstract]. *J Athl Train.* 1999;34(suppl 2):S84.
94. Knight KL. Editorial: removing football helmet facemasks. *J Athl Train.* 1992;27:197.
95. Knox KE, Kleiner DM. A description of how chin straps are attached to high school football helmets [abstract]. *J Athl Train.* 2000;35(suppl 2):S62.
96. Knox KE, Kleiner DM. The effectiveness of EMT shears for face mask removal [abstract]. *J Athl Train.* 1996;31(suppl 2):S17.
97. Knox KE, Kleiner DM. The efficiency of tools used to retract a football face mask. *J Athl Train.* 1997;32:211-215.
98. Kraus JF, Anderson BD, Mueller CE. The effectiveness of a new touch football helmet to reduce head injuries. *J Sch Health.* 1970;40:496-500.
99. LaPrade RF, Schnetzler K, Boxterman RJ, et al. Cervical spine alignment in the immobilized ice hockey player: a computed tomographic analysis of the effects of helmet removal. *Am J Sports Med.* 2000;28:800-803.
100. Lawrence DW, Stewart GW, Christy DM, et al. High school football-related cervical spine injuries in Louisiana: the athlete's perspective. *J La State Med Soc.* 1997;149:27-31.
101. Lennarson PJ, Smith D, Todd MM, et al. Segmental cervical spine motion during orotracheal intubation of the intact and injured spine with and without external stabilization. *J Neurosurg.* 2000;92:201-206.
102. Li AE, Fishman EK. Cervical spine trauma: evaluation by multidetector CT and three-dimensional volume rendering. *Emerg Radiol.* 2003;10:34-39.
103. Long SE, Reid SE, Sweeney HJ, et al. Removing football helmets safely. *Phys Sportsmed.* October 1980;8:119.
104. Martin V. Football rules seek to curb head blocking. *Phys Sportsmed.* March 1976;4:23-24.
105. McGuine TA, Hart C, Nass SJ. Football helmet fitting in Wisconsin high schools [abstract]. *J Athl Train.* 1995;30:S39.
106. McGuine TA, Nass SJ. Evaluation of football helmet fit in high school football players [abstract]. *Med Sci Sports Exerc.* 1994;26:S13.
107. McGuine TA, Nass SJ. Football helmets: are they fitted properly? A survey of high school football coaches' knowledge and policies for fitting football helmets [abstract]. *Med Sci Sports Exerc.* 1995;27:S53.
108. McIntosh AS, Janda D. Evaluation of cricket helmet performance and comparison with baseball and ice hockey helmets. *Br J Sports Med.* 2003;37:325-330.

109. McSwain NE. Techniques of helmet removal from injured patients. *Bull Am Coll Surg.* 1981;66:19-21.
110. McVey R, Gruber D, Hodges J. Neck pain in a collegiate football player [abstract]. *J Athl Train.* 2001;36(suppl 2):S70.
111. Metz CM, Kuhn JE, Greenfield ML. Cervical spine alignment in immobilized hockey players: radiographic analysis with and without helmets and shoulder pads. *Clin J Sport Med.* 1998;8:92-95.
112. Meyer RD, Daniel WW. The biomechanics of helmets and helmet removal. *J Trauma.* 1985;25:329-332.
113. Miller GL, Kleiner DM. Esophageal tracheal Combitube intubation and football equipment [abstract]. *Med Sci Sports Exerc.* 2002;35(suppl 5):S102.
114. Mower WR, Hoffman JR, Pollack CV, Zucker MI, Browne BJ, Wolfson AB. Use of plain radiography to screen for cervical spine injuries. *Ann Emerg Med.* 2001;38:1-7.
115. Muckart DJ, Bhagwanjee S, van der Merwe R. Spinal cord injury as a result of endotracheal intubation in patients with undiagnosed cervical spine fractures. *Anesthesiology.* 1997;87:418-420.
116. Mueller FO, Cantu RC. Annual survey of catastrophic football injuries (1977-2002) [National Center for Catastrophic Sport Injury Research Web site]. 2003. Available at: www.unc.edu/depts/nccsi.
117. National Collegiate Athletic Association. Guideline 4-F: guidelines for helmet fitting and removal in athletes. In: Schlupe C, ed. *2003-2004 NCAA Sports Medicine Handbook.* 16th ed. Indianapolis, Ind: National Collegiate Athletic Association; 2003:79-81.
118. Neifeld GL, Keene JG, Hevesy G, et al. Cervical injury in head trauma. *J Emerg Med.* 1988;6:203-207.
119. Nelson DE, Rivara FP, Condie C. Helmets and horseback riders. *Am J Prev Med.* 1994;10:15-19.
120. Nypaver M, Treloar D. Neutral cervical spine positioning in children. *Ann Emerg Med.* 1994;23:208-211.
121. Osberg JS, Schneps SE, Di Scala C, et al. Skateboarding: more dangerous than roller-skating or in-line skating. *Arch Pediatr Adolesc Med.* 1998;152:985-991.
122. O'Sullivan PT, Decoster LC, Swartz EE. Comparison of football facemask retraction and removal times [abstract]. *J Athl Train.* 2002;37(suppl 2):S37.
123. Palumbo MA, Hulstyn MJ, Fadale PD, et al. The effect of protective football equipment on alignment of the injured cervical spine: radiographic analysis in a cadaveric model. *Am J Sports Med.* 1996;24:446-453.
124. Patel MN, Rund DA. Emergency removal of football helmets. *Phys Sportsmed.* October 1994;22:57-58.
125. Pearl AJ, Mayer PW. Neck motion in the high school football player: observations and suggestions for diminishing stresses on the neck. *Am J Sports Med.* 1979;7:231-233.
126. Pearson D, Gearhart T, Horodyski M, et al. A comparison of the effectiveness of helmet fit during immobilization in youth and professional ice hockey players [abstract]. *Med Sci Sports Exerc.* 2000;15:298-299.
127. Pearson DB, Hoenshel RW, Almquist JL, et al. The anvil pruner vs the modified PVC pipe cutter [abstract]. *J Athl Train.* 2001;37(suppl 2):S38.
128. Pearson DB, Hoenshel RW, Kleiner DM. An evaluation of the Bike loop-strap vs the Schutt loop-strap [abstract]. *J Athl Train.* 2001;36(suppl 2):S69.
129. Peris MD, Donaldson WF, Towers J, et al. Helmet and shoulder pad removal in suspected cervical spine injury human control model. *Spine.* 2002;27:995-998.
130. Pettersen JA. Does rugby headgear prevent concussions? Attitude of Canadian players and coaches. *Br J Sports Med.* 2002;36:19-22.
131. Podolsky S, Baraff LJ, Simon RR, et al. Efficacy of cervical spine immobilization methods. *J Trauma.* 1983;23:461-465.
132. Prinsen RKE, Syroituik DG, Reid DC. Position of the cervical vertebrae during helmet removal and cervical collar application in football and hockey. *Clin J Sport Med.* 1995;5:155-161.
133. Putnam LA. Alternative methods for football helmet face mask removal. *J Athl Train.* 1992;27:170-172.
134. Quencer RM, Nunez D, Green BA. Controversies in imaging acute cervical spine trauma. *Am J Neuroradiol.* 1997;18:1866-1868.
135. Quinn DI. Dissecting the rugby tackle: do shoulder pads contribute to cervical spine injuries? *Med J Aust.* 1998;169:501-502.
136. Quinn TM. Touchdown! Immobilization of the professional football player. *Emerg Med Serv.* October 2001;30:71-75.
137. Quinn TM, Miller GL, Kleiner DM. Attitudes about football equipment removal procedures among fire rescue personnel [abstract]. *Med Sci Sports Exerc.* 2002;35(suppl 5):S103.
138. Ransone J, Kersey R, Walsh K. The efficacy of the rapid form cervical vacuum immobilizer in cervical spine immobilization of the equipped football player. *J Athl Train.* 2000;35:65-69.
139. Ray R. Helmets and face masks [letter to the editor]. *J Athl Train.* 1992;27:294.
140. Ray RR, Luchies C, Abfall MK, et al. Cervical spine motion in football players during three airway exposure techniques. *J Athl Train.* 2002;37:172-177.
140. Ray R, Luchies C, Bazuin D, et al. Airway preparation techniques for the cervical spine-injured football player. *J Athl Train.* 1995;30:217-221.
142. Redden WW, Kleiner DM, Holcomb WR. The effects of gender, hand size, and grip strength on the ability to remove a football helmet facemask [abstract]. *J Athl Train.* 1998;33(suppl 2):S43.
143. Rehberg RS. Facemask removal tools come in all shapes, styles. *NATA News.* 1999;8:8-9.
144. Rehberg RS, Kleiner DM, Knox KE. A description of how chin straps are attached to high school football helmets in New Jersey [abstract]. *J Athl Train.* 2002;37(suppl 2):S38.
145. Reynen PD, Clancy WG. Cervical spine injury, hockey helmets, and facemasks. *Am J Sports Med.* 1994;22:167-170.
146. Roberts WO. Hitting in amateur ice hockey: not worth the risk. *Phys Sportsmed.* November 1999;27:35.
147. Robey JM. Contribution of design and construction of football helmets to the occurrence of injuries. *Med Sci Sports Exerc.* 1972;4:170-174.
148. Sanville M, Hoenshel RW, Angotti DD, et al. The sharpness of facemask removal tools and performance [abstract]. *J Athl Train.* 2000;35(suppl 2):S60.
149. Scher AT. Rugby injuries to the cervical spine and spinal cord: a 10-year review. *Clin Sports Med.* 1998;17:195-205.
150. Schleeauf K, Ross SE, Civil ID, et al. Computed tomography in the initial evaluation of the cervical spine. *Ann Emerg Med.* 1989;18:815-817.
151. Schneider RC, Reifel E, Crisler HO, et al. Serious and fatal football injuries involving the head and spinal cord. *JAMA.* 1961;177:362.
152. Schriger DL, Larmon B, LeGassick T, et al. Spinal immobilization on a flat backboard: does it result in neutral position of the cervical spine. *Ann Emerg Med.* 1991;20:878-881.
153. Segan RD, Cassidy C, Bentkowski J. A discussion of the issue of football helmet removal in suspected cervical spine injuries. *J Athl Train.* 1993;28:294-305.
154. Shaffer MA, Doris PE. Limitation of the cross-table lateral view in detecting cervical spine injuries: a retrospective study. *Ann Emerg Med.* 1981;10:508-513.
155. Silloway KA, McLaughlin RE, Edrich RC, et al. Clavicular fractures and acromioclavicular joint locations in lacrosse: preventable injuries. *J Emerg Med.* 1985;3:117-121.
156. Slucky AV, Potter HG. Use of magnetic resonance imaging in spinal trauma: indications, techniques, and utility. *J Am Acad Orthop Surg.* 1998;6:134-145.
157. Smith M, Bourn S, Larmon B. Ties that bind: immobilizing the injured spine. *J Emerg Med Serv.* 1987;4:28-35.
158. Springer BL, Kleiner DM. Effectiveness of video training emergency medicine physicians on athletic spine injuries [abstract]. *Med Sci Sports Exerc.* 2002;35:S220.
159. Stenger J, Lawton EA, Wright J, et al. Mouthguards: protection against shock to head, neck, and teeth. *J Am Dent Assoc.* 1964;69:273-281.

160. Stephenson A, Horodyski MB, Meister K, et al. Cervical spine alignment in the immobilized ice hockey player: radiographic analysis before and after helmet removal [abstract]. *J Athl Train*. 1999;34:S27.
161. Stiell IG, Wells GA, Vandemheen KL, et al. The Canadian C-spine rule for radiography in alert and stable trauma patients. *JAMA*. 2001;286:1841-1848.
162. Surace AF, Goldfuss AJ, Hauth JM, et al. Effect of selected tools on facemask removal and head motion [abstract]. *J Athl Train*. 2000;35(suppl 2):S62.
163. Swartz EE, Armstrong CW, Rankin JM, et al. A 3-dimensional analysis of face-mask removal tools in inducing helmet movement. *J Athl Train*. 2002;37:178-184.
164. Swartz E, Norkus S. Riddell helmet research continues [letter to the editor]. *NATA News*. 2003;3:62.
165. Swartz EE, Norkus SA, Armstrong CW, et al. Face-mask removal: movement and time associated with cutting of the loop straps. *J Athl Train*. 2003;38:120-125.
166. Swenson TM, Laueran WC, Donaldson WF, et al. Cervical spine alignment in the immobilized football player: radiographic analysis before and after helmet removal. *Am J Sports Med*. 1997;25:226-230.
167. Tarazi F, Dvorak MFS, Wing PC. Spinal injuries in skiers and snowboarders. *Am J Sports Med*. 1999;27:177-180.
168. Tierney RT, Maldjian C, Mattacola CG, et al. Cervical spine stenosis measures in normal subjects. *J Athl Train*. 2002;37:190-193.
169. Tierney RT, Mattacola CG, Sitler MR, et al. Head position and football equipment influence cervical spinal cord space during immobilization. *J Athl Train*. 2002;37:185-189.
170. Torg JS. Epidemiology, pathomechanics, and prevention of football-induced spinal cord trauma. *Exerc Sport Sci Rev*. 1992;20:321-338.
171. Torg JS, Ramsey-Emrhein JA. Management guidelines for participation in collision activities with congenital, developmental, or postinjury lesions involving the cervical spine. *Clin J Sport Med*. 1997;7:273-291.
172. Torg JS, Vegso JJ, O'Neill MJ, et al. The epidemiologic, pathologic, biomechanical, and cinematographic analysis of football-induced cervical spine trauma. *Am J Sports Med*. 1990;18:50-57.
173. Torg JS, Vegso JJ, Torg E. *Prevent Paralysis: Don't Hit With Your Head* [video production]. Philadelphia, Pa: University of Pennsylvania Sports Medicine Center and the National Federation of State High School Association; 1992.
174. Trupiano TP, Sampson ML, Weise MW. Fracture of the first cervical vertebrae in a high school player: a case report. *J Athl Train*. 1997;32:159-162.
175. Van Camp LA, Vanderschot PM, Sabbe MB, et al. The effect of helmets on the incidence and severity of head and cervical spine injuries in motorcycle and moped accident victims: a prospective analysis based on emergency department and trauma center data. *Eur J Emerg Med*. 1998;5:207-211.
176. Veenema K, Greenwald R, Kamali M, et al. The initial lateral cervical spine film for the athlete with a suspected neck injury: helmet and shoulder pads on or off? *Clin J Sport Med*. 2002;12:123-126.
177. Vegso JJ, Lehman RC. Field evaluation and management of head and neck injuries. *Clin Sports Med*. 1987;6:1-15.
178. Vieson M, Wimer JW. Attitudes about football helmet removal procedures from students in a paramedic education classroom [abstract]. *J Athl Train*. 1998;33(suppl 2):S61.
179. Virgin H. Cineradiographic study of football helmets and the cervical spine. *Am J Sports Med*. 1980;8:310-317.
180. Waeckerle JF, Kleiner DM. Protective athletic equipment and cervical spine imaging [editorial]. *Ann Emerg Med*. 2001;38:65-67.
181. Waninger KN. The efficacy of the rapid form cervical vacuum immobilizer in cervical spine immobilization of the equipped football player [letter to the editor]. *J Athl Train*. 2001;36:361-362.
182. Waninger KN. On-field management of potential cervical spine injury in helmeted football players: leave the helmet on! *Clin J Sport Med*. 1998;8:124-129.
183. Waninger KN. On-field management of the injured football player [response to letter to the editor]. *Clin J Sport Med*. 2000;10:82-83.
184. Waninger KN, Richards JG, Pan WT, et al. An evaluation of head and cervical spine movement in backboard-immobilized helmeted football, lacrosse, and ice hockey players. *Clin J Sport Med*. 2001;11:82-86.
185. Waninger KN, Rothman M, Foley J, et al. Evaluation of the adequacy of CT in the cervical spine imaging of the American Football Player with helmet and shoulder pads on. Abstract presented at: Annual Meeting of the American Society of Spine Radiology; February 19-23, 2003; Scottsdale, Ariz; Pennsylvania Radiological Society Scientific Exhibits, Hershey, Pa, 2003.
186. Waninger KN, Rothman M, Heller M. Evaluation of the adequacy of MRI in the cervical spine imaging of the American football player with helmet and shoulder pads on. *Clin J Sport Med*. 2003;13:339-343.
187. Watt GM, Finsc CF. Preventing equestrian injuries: locking the stable door. *Sports Med*. 1996;22:187-197.
188. Wetzler MJ, Akpata T, Laughlin W, et al. Occurrence of cervical spine injuries during the rugby scrum. *Am J Sports Med*. 1998;26:177-180.
189. White AA, Johnson RM, Panjabi MM, et al. Biomechanical analysis of clinical stability in the cervical spine. *Clin Orthop*. 1975;109:85-95.
190. Wilson BD. Protective headgear in rugby union. *Sports Med*. 1998;25:333-337.
191. Winters JE. Commentary: role of properly fitted mouthguards in prevention of sport-related concussion. *J Athl Train*. 2001;36:339-341.
192. Zeal JA, Kleiner DM, Pearson DB, et al. The effects of modifying the standard loop-strap arrangement on face mask removal [abstract]. *J Athl Train*. 2002;37(suppl 2):S87-S88.